

# Effects of Parallax and Distortion in Total Ankle Arthroplasty

Joseph R Brown, DPM<sup>1</sup>, Zachary P Hill, DPM<sup>1</sup>, Ross Groeschl, DPM<sup>1</sup>, Brian Steginsky, DO<sup>2</sup>, Robert W Mendicino, DPM, FACFAS<sup>2</sup>

1. Resident, OhioHealth Grant Medical Center, Columbus, OH 2. Teaching Faculty, OhioHealth Grant Medical Center, Columbus, OH

## STATEMENT OF PURPOSE

The purpose of this study was to evaluate the prevalence and degree of parallax/distortion in intraoperative fluoroscopic images during total ankle arthroplasty (TAA).

## METHODOLOGY

A retrospective review of all total ankle arthroplasties at a level 1 trauma center performed by two surgeons (R.M. and B.S.) between August 2019-April 2023 were reviewed. Two types of modern total ankle prostheses were utilized in this study. Fixed bearing implants were utilized, either with or without an intramedullary stem.

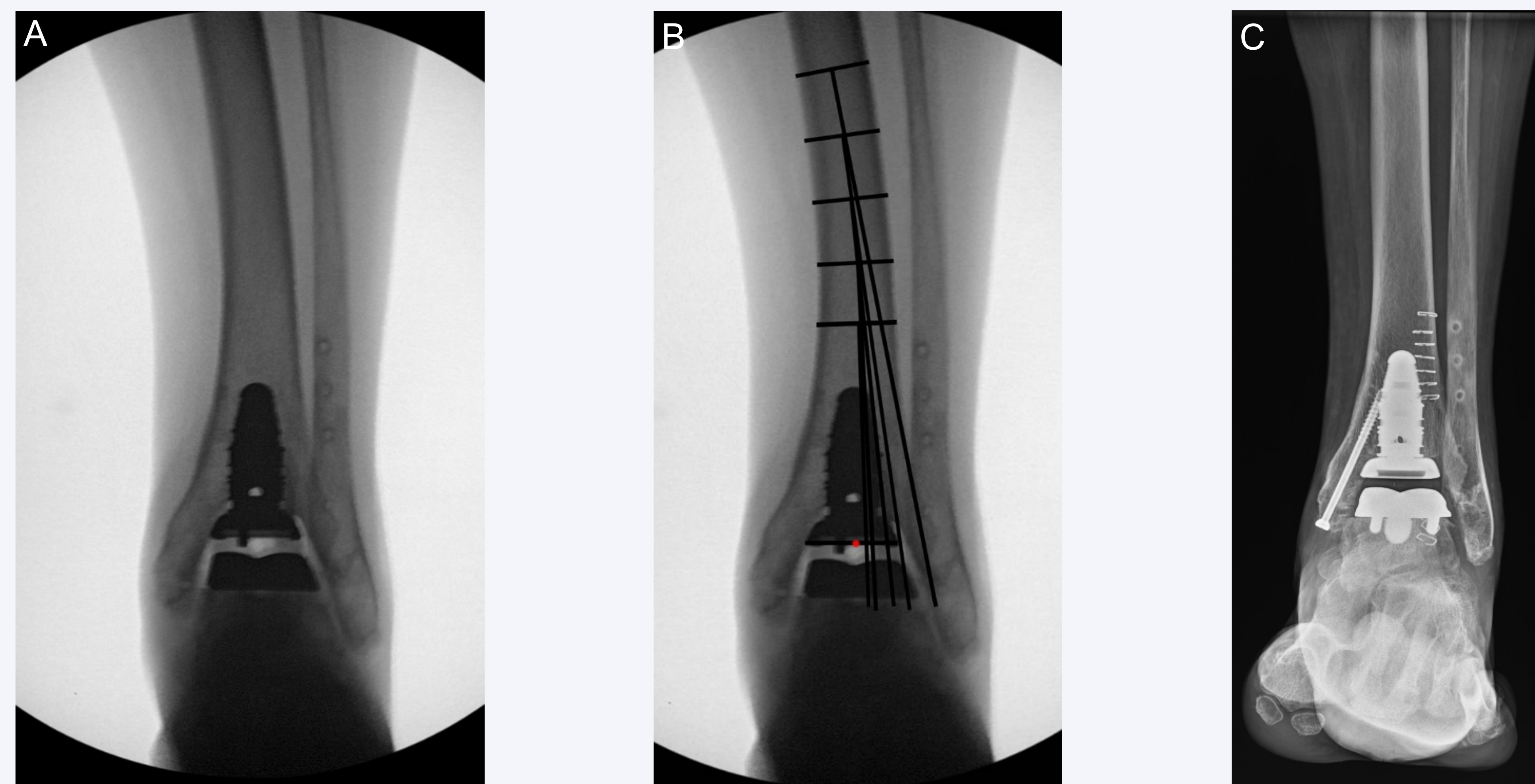
Intraoperative fluoroscopic images obtained on patients undergoing TAA were reviewed for any obvious parallax distortion. Images were viewed on computerized software and were then printed for analysis. Standard anteroposterior radiographic views were evaluated. If any obvious parallax distortion was noted, angular measurements were performed for further evaluation.

Images with obvious parallax/distortion were imported into Photoshop 2024, version 25.4 (Adobe, San Jose, CA). Lines were drawn for the respective angles listed below and were measured utilizing the ruler tool. A horizontal line was drawn at the distal tibial tray to represent the distal tibial component. A red dot was placed at the center of this line to represent the center of the tibiotalar joint. The tibia was marked at 2-centimeter intervals from the proximal stem of the implant to create tibial zones. Tibial zones were labeled in sequential order from distal to proximal. The AAT was drawn at the mid-diaphysis of each respective zone (Figure 1). The aLDTA and AAD were measured for each segment. The aLDTA was measured as the angle between the anatomical axis of the tibia and the articular surface of the tibia, or tibial component. The AAD was measured as the amount of deviation, either medially or laterally, from the center of the tibiotalar joint (Tables 1-3).

## LITERATURE REVIEW

Fluoroscopy utilization is an indispensable tool for surgeons, particularly when performing a TAA. Parallax distortion is the apparent difference in direction of an object when visualized from two different points that are not in a straight line with the object.<sup>1</sup> This occurs due to the inherent variation of angled beams within fluoroscopy units, as well as the potential inaccurate projection of the C-arm on the intended object. Differences in parallax distortion can be noted on comparison of intraoperative fluoroscopic images and postoperative plain film radiographs. Parallax can introduce errors in perceived position of anatomical landmarks, potentially leading to inaccurate implant placement. A malpositioned prosthesis can lead to impingement, increased risk of subsidence, and component loosening.<sup>2</sup> One potential cause for prosthesis malalignment is inadequate fluoroscopic imaging of the tibial axis.<sup>3</sup> The apparent shift of anatomical landmarks caused by parallax/distortion can result in angular deviation and linear displacements of implant components. Literature on total knee and total hip arthroplasties has emphasized these effects.<sup>4-7</sup> Talbot et al reported on femoral component malrotation due to parallax errors in total knee arthroplasty. They emphasized the importance of identifying reproducible anatomical landmarks and removing parallax errors to limit the malrotation of components.<sup>4</sup> Thorne et al described changes in acetabular cup positioning due to parallax distortion and positioning of the fluoroscopy unit.<sup>7</sup> However, no literature has focused on the effect of parallax on total ankle arthroplasties.

## RESULTS



**Figure 1:** Radiographic images of "TAA 1". **A)** Intraoperative fluoroscopic image with significant parallax distortion appreciated at the proximal tibia. **B)** Same fluoroscopic image with angular illustrations. Red circle representing the center of the tibiotalar joint. Tibial zones marked at 2-centimeter intervals. The AAT was drawn at the mid-diaphysis of each zone. The aLDTA and AAD were measured from the AAT of each zone. **C)** Postoperative flat plate radiograph. One can appreciate the lack of parallax/distortion of the tibia.

	Zone 1	Zone 2	Zone 3	Zone 4	Zone 5
TAA 1	90°	91°	94°	100°	98°
TAA 2	86°	86°	91°	91°	N/A
TAA 3	90°	91°	91°	92°	N/A
TAA 4	90°	86°	86°	89°	91°
TAA 5	91°	95°	98°	N/A	N/A
TAA 6	84°	88°	86°	91°	N/A

**Table 1:** The lateral distal tibial angle (aLDTA) measured at each 2cm zone from the proximal stem of the implant.

	Zone 1	Zone 2	Zone 3	Zone 4	Zone 5
TAA 1	0.8 lateral	2.0 lateral	6.6 lateral	17.3 lateral	13.4 lateral
TAA 2	0.5 lateral	1.8 lateral	4.4 medial	4.9 medial	N/A
TAA 3	2.2 medial	2.6 medial	4.2 medial	7.9 medial	N/A
TAA 4	2.2 medial	1.1 lateral	1.8 lateral	4.2 medial	8.2 medial
TAA 5	1.3 lateral	6.0 lateral	8.3 lateral	N/A	N/A
TAA 6	2.4 lateral	2.4 medial	0.8 medial	8.0 medial	N/A

**Table 2:** The anatomic axis deviation (AAD) measured at each 2cm zone from the proximal stem of the implant.

Variable	Value
Cases with obvious parallax/distortion	6/18 (33.3%)
Average aLDTA	90.6° (84-100)
Average aLDTA at proximal tibial zone	93.6° (91-100)
Average AAD	4.6mm (0.5-17.3)
Medial AAD Range	0.5-17.3mm
Lateral AAD Range	0.8-8.2mm

**Table 3:** A summary of radiographic data obtained in a total of 6/18 (33.3%) cases that had obvious parallax/distortion.

## ANALYSIS AND DISCUSSION

A total of 22 TAAs were performed. 4 cases were excluded due to inadequate imaging. 6/18 (33.3%) of cases had obvious parallax distortion. The average aLDTA was 90.6°, which increased to 93.8° at the most proximal tibial zone. Furthermore, we found an average AAD of 4.6mm, with a range from 0.5-17.3mm lateral to 0.8-8.2mm medial. As the normal aLDTA is 89 degrees and the anatomic axis should be centered within the ankle joint, deviation from this can cause difficulty with implant placement. Parallax can distort the appearance of the tibia on intraoperative fluoroscopic images. Surgeons should be aware of the potential impact of parallax/distortion on TAA and ways to mitigate these deleterious effects.

Implant positioning is critical to a successful outcome in total ankle arthroplasties. Parallax distortion can lead to errors in surgical technique and malalignment of the prosthesis. In a normal ankle joint, there is a valgus moment as the weight-bearing axis passes slightly lateral from the midline of the tibia to the calcaneus.<sup>8</sup> When performing a TAA, the weight-bearing axis should be maintained with a valgus moment. In their study of 50 TAAs, Schubert et al found that malalignment of the prosthesis could occur secondary to inadequate fluoroscopic imaging of the tibial axis.<sup>3</sup> The findings of this study emphasize the need for strategies to minimize parallax-related errors during TAA surgery.

Several approaches can be considered to limit the impact of parallax in TAA. Multiple authors have emphasized the importance of ensuring the object being imaged is within the center of the field of view (FOV).<sup>9-11</sup> Weldon et al. reported that measurement errors increase by 14% per 10mm of horizontal C-arm offset. This is negated, with a minimal effect, when the image is obtained within 5mm of the true center of the object.<sup>9</sup> Additionally, narrowing the FOV or increasing the image magnification, can decrease the amount of distortion.<sup>10</sup> Surgeons can work together with radiologist technicians to adjust the position of the X-ray beam relative to the object of interest in order to alter the apparent bony alignment.<sup>10,12</sup> Although difficult to control, it is important to note that distortion can occur when electrons veer off course secondary to external electromagnetic fields such as magnetic resonance imaging machines and the central power-supply grid.

## CONCLUSION

In conclusion, this review provides valuable insights into the impact of parallax on total ankle arthroplasties. Parallax may distort the appearance of the tibia, as well as the normal tibial anatomical and mechanical axis, on intraoperative fluoroscopic images. Surgeons should be aware of the challenges posed by parallax in implant positioning and ways to mitigate these deleterious effects. Further research is warranted to validate the findings of this study and explore strategies to minimize the impact of parallax on outcomes.

## REFERENCES

- Buckle CE, Udawatta V, Straus CM. Now you see it, now you don't: visual illusions in radiology. *Radiographics*. 2013 Nov-Dec;33(7):2087-102.
- Cody EA, Benjano-Pineda L, Lachman JF, Taylor MA, Gussman EB, DeCiro JK, Easley ME, Nunley JA 2nd. Risk Factors for Failure of Total Ankle Arthroplasty With a Minimum Five Years of Follow-up. *Foot Ankle Int*. 2019 Mar;40(3):249-258.
- Schubert JM, Patel S, Zanitsky E. Perioperative complications of the Agility total ankle replacement in 50 initial, consecutive cases. *J Foot Ankle Surg*. 2006 May-Jun;45(3):139-46.
- Talbot S, Dimitriou P, Mullen M, Bartlett J. Referencing the sulcus line of the trochlear groove and removing intraoperative parallax errors improve femoral component rotation in total knee arthroplasty. *Knee Surg Sports Traumatol Arthrosc*. 2017 Sep;25(9):2743-2750.
- Franssen JJ, Kahn TL, Anderson LA, Palt CE, Peters CL, Gilliland JM. Managing Hip-Spine Concepts in the Direct Anterior Approach With Use of Fluoroscopy. *J Arthroplasty*. 2021 Jul;36(7S):S104-S110.
- Asnis SE, Heller YY. Total Hip Arthroplasty Templating: A Simple Method to Correct for Radiograph Magnification. *Orthopedics*. 2019 May 1;42(5):e322-e325.
- Thorne TJ, Wright AR, Opanova MI, Mitsumori LM, Lawton DR, Unehassami EM, Nakasone CK. Impact of intraoperative fluoroscopic beam positioning relative to the hip and pelvis on perceived acetabular component position. *J Orthop*. 2022 Nov 24;35:115-119.
- Griesberg J, Hansen ST Jr. Ankle replacement: management of associated deformities. *Foot Ankle Clin*. 2022;7(4):721-36. vi.
- Weldon M, Arenas A, Abraham A, Halder A, Warth RJ, Mansour A 3rd. Attention to Detail: The Effect of Fluoroscopic Parallax on Limb Alignment Assessment During Corrective Osteotomy. *J Am Acad Orthop Surg Glob Res Rev*. 2023 Feb 13;7(2):e22.00289.
- Keating TC, Bohl DD, Hamid KS. A Review of Fluoroscopic Image-Intensifier Artifacts and the Next Generation of Isocentric C-Arm Imaging. *JBUS Rev*. 2019 Dec;6(12):14.
- Kagan BD, Roberts MS, Haines MA, Blankstein M, Schottel PC. Intraoperative Comparative Femoral Rotation Imaging: Do not Overlook Parallax. *J Orthop Trauma*. 2022 Aug 1;36(8):420-425.
- McArthur JR, Mackies P, Wainwright D. Resemblance of valgus malalignment of the distal tibia in 15-degree craniocaudal radiographs. *J Orthop Surg (Hong Kong)*. 2013 Dec;21(3):337-9.