

A Case Study of Violent Psychosis Secondary to Previously Undiagnosed Chemo-Radiation Induced Hypothyroidism

Alexander Weiss¹, Adam Levin, MD², Kiana Dash¹ and Elenora Sikic-Klisovic, MD²

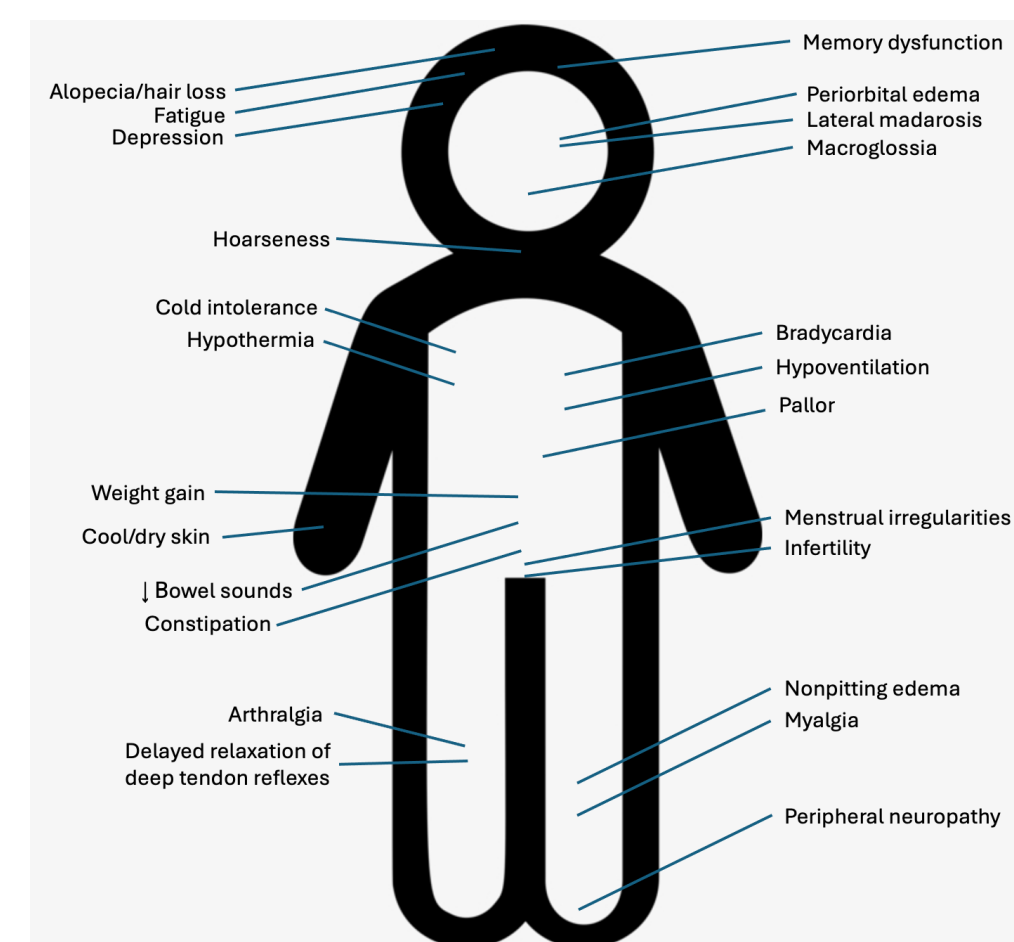
COLLEGE OF
MEDICINE

INTRODUCTION

Hypothyroidism is the most common thyroid disorder, affecting over 5% of the general population worldwide.¹ Defined by high serum thyroid-stimulating hormone (TSH) and low thyroxine (T4) concentrations, hypothyroidism presents with a variety of physical and cognitive symptoms related to thyroxine's extensive involvement in nuclear and cytoplasmic signaling pathways (See Figure 1). Less commonly appreciated is hypothyroidism's relationship with psychosis. An often-overlooked differential diagnosis for patients suffering from new-onset hallucinations and delusions, hypothyroidism is a highly treatable cause of secondary psychosis.² Coined myxedema psychosis (MP), hallucinations and delusions occur in <2% of patients with hypothyroidism.³ Meanwhile, 26-37% of MP cases present without any classic signs or symptoms of hypothyroidism, essentially serving as the first manifestation of thyroid pathology.

This case describes the emergence of a paranoid, homicidal psychosis in the setting of previously undiagnosed chemoradiation-induced hypothyroidism which promptly responded to levothyroxine therapy.

Figure 1. Classic signs and symptoms of hypothyroidism



CASE PRESENTATION

Background

- 68-year-old Caucasian male escorted to ED by police after discharging firearm at home
- Patient was experiencing threatening audiovisual hallucinations of late wife and her "new boyfriend," prompting him to defend himself from perceived physical harm
- Past medical history: cT3N2c hypopharyngeal SCC 1.5 months s/p 5 weeks cisplatin chemotherapy and 70 Gy neck radiotherapy
- Psychiatric history: Major Depressive Disorder established 5 months prior to presentation, managed with venlafaxine 37.5 mg BID
- Perceptual disturbances first noted by daughter one month prior, with accounts of paranoia starting weeks before admission
- Somatic complaints: hoarse voice and difficulty ambulating

Exam

- Vitals:** hypertensive
- Physical exam:** unremarkable
- Psychiatric interview:**
 - Appearance: disheveled
 - Attention: impaired
 - Orientation: person, situation
 - Behavior: pleasant, cooperative
 - Mood: depressed, anxious, frightened
 - Affect: congruent
 - Motor activity: grossly normal
 - Speech: soft, latent, intermittently muddled
 - Thought process: disorganized and circumstantial
 - SI/HI: denied by patient
 - Delusions: paranoid, reference
 - Hallucinations: auditory and visual
 - Memory: poor recent and remote
 - Insight/judgement: poor
 - Impulse control: grossly intact
 - Fund of knowledge: intact to conversation
 - Language/vocabulary: normal
 - Cognition: impaired

Work-up

- Blood work: mild anemia, thrombocytopenia, and hyponatremia
- UDS: negative
- Sexually transmitted illness serologies, urinalysis, and vitamin B and D studies normal
- TSH elevated to 115.05 μ IU/mL and free T4 depressed to 0.34 ng/dL
- Head CT and brain MRI demonstrated changes consistent with chronic microvascular disease

Initial Management

- Olanzapine 2.5 mg nightly started
- Home prescription of venlafaxine changed to 75 mg in the morning for complaints of poor sleep
- Hospital day (HD) #2: oral levothyroxine 100 mcg daily initiated

Hospital Course

- HD#3:** onset of abnormal involuntary movements of extremities and face concerning for seizure-like activity
 - EEG: continuous and symmetric background without focal or diffuse abnormalities
 - Neurology consult: manifestation of REM sleep behavior disorder, raising concern for underlying alpha-synucleinopathy
- HD#4:** repeat blood work revealed TSH of 118.672 μ IU/mL and free T4 to 0.35 ng/dL
 - Transitioned to IV levothyroxine
- HD#5:** significantly diminished hyperkinesia noted
- Improvements to alertness and mentation continued in coming days while perceptual disturbances became infrequent and less bothersome
- HD#8:** TSH and T4 improved to 112.67 μ IU/mL and 0.67 ng/dL respectively
 - Transitioned back to oral levothyroxine
- HD#14:** patient displayed no residual signs of cognitive dysfunction or psychosis. Discharged home with scheduled endocrinology follow-up and referrals for outpatient polysomnography and neuropsychiatric evaluation

DISCUSSION³

- Research suggests psychosis in MP may be due to alterations in neurometabolic activity and monoaminergic messaging
- MP highly responsive to levothyroxine therapy, with time to resolution frequently <2 weeks
- Mean TSH and free T4: 93 μ IU/mL [60-139 μ IU/mL] and 0.2 ng/dL [0.13-0.39 ng/dL]
- Literature suggests IV levothyroxine may expedite recovery compared to oral therapy
- MP frequently exhibits complete return to neurocognitive baseline post-treatment
- Characterization of MP limited to sporadic case studies given low incidence and atypical presentation
- Validated scales and diagnostic criteria for MP are lacking

CONCLUSIONS

- This case highlights the importance of clinical curiosity more broadly as well as explicitly in cases of chemoradiation therapy.
- By identifying an organic, secondary cause of psychosis in this case, we were able to be more proactive in our management.
- Despite wide variability in presentation and uncomplicated reversibility with levothyroxine therapy, validated diagnostic tools for MP are currently lacking.
- Easily missed in patients without a previous diagnosis of hypothyroidism, further research into MP is needed to better explicate its underpinnings and avoid future incidences of violence.

BIBLIOGRAPHY

- Chiovato L, Magri F, Carlé A. Hypothyroidism in context: Where we've been and where we're going. *Adv Ther.* 2019;36(Suppl 2):47-58. doi:10.1007/s12325-019-01080-8
- McKee J, Brahm N. Medical mimics: Differential diagnostic considerations for psychiatric symptoms. *Ment Health Clin.* 2016;6(6):289-296. doi:10.9740/mhc.2016.11.289
- Mohamed MFH, Danjuma M, Mohammed M, et al. Myxedema Psychosis: Systematic Review and Pooled Analysis. *Neuropsychiatr Dis Treat.* 2021;17:2713-2728. doi:10.2147/NDT.S318651

